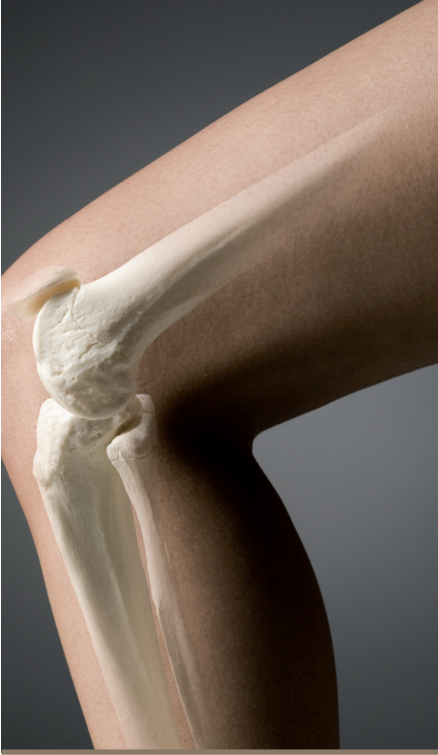


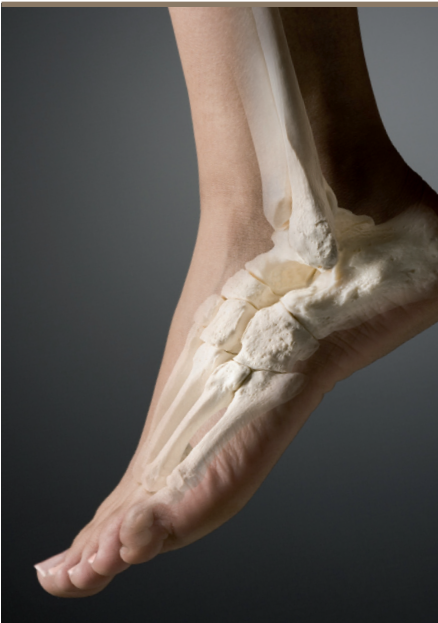
BAPRAS

British Association of Plastic
Reconstructive and Aesthetic Surgeons

Standards for the management of

OPEN FRACTURES OF THE LOWER LIMB



A SHORT GUIDE

British
Orthopaedic
Association



WHO SHOULD READ THIS GUIDE?

Standards for the management of open fractures of the lower limb details the optimal treatment for patients with these challenging injuries. Drawing on an extensive review of the published evidence and their personal experience, the authors set out each stage of the management pathway, including what to do if complications arise.

Of relevance to pre-hospital, emergency room and hospital clinicians, each chapter contains key recommendations for the standards of care that should be delivered and practical advice.

Containing important new guidance for getting the best outcomes, the *Standards* are an essential reference text for orthopaedic, plastic surgery, emergency medicine, and rehabilitation specialists who treat these injuries as well for those who plan and commission trauma care.

Endorsed by the Councils of the British Association of Plastic, Reconstructive and Aesthetic Surgeons and the British Orthopaedic Association, the *Standards for the management of open fractures of the lower limb* replace previous guidelines in the UK and will have worldwide relevance.

This short guide contains only the key recommendations from the Standards. Readers wishing to review the evidence-base behind them should refer to the full *Standards* publication. Details of how to obtain a copy may be found on our websites: www.bapras.org.uk and www.boa.ac.uk

CONTENTS

1. Foreword	02
2. Introduction	05
3. The working group	06
4. Principal recommendations	07
• Specialist centres	
• Emergency management	
• Antibiotic prophylaxis	
• Timing of wound debridement	
• Soft tissue debridement	
• Bone debridement	
• Degloving injuries	
• Classification	
• Temporary wound dressings	
• Techniques of skeletal stabilisation	
• Timing of soft tissue reconstruction	
• Type of soft tissue reconstruction	
• Compartment syndrome	
• Vascular injuries	
• Foot and ankle	
• When things go wrong with soft tissues	
• When things go wrong with bone	
• Guidelines for amputation	
• Outcome measures	
• Management of severe open fractures in children	

Acknowledgements

Back cover



The British Association of Plastic, Reconstructive and Aesthetic Surgeons (BAPRAS) and the British Orthopaedic Association (BOA) have been working to promote the joint care of patients with severe open fractures of the lower limb by plastic and orthopaedic surgeons to minimise complications and optimise outcomes.

These *Standards for the management of open fractures of the lower limb* go beyond this to provide an evidence-based approach to improve the management of these uncommon, difficult injuries. The authors have built on the previous guidelines to define the standards of treatment and provide clear guidance of how these patients should be managed. They have addressed all aspects of the care of the patient, from initial assessment through to reconstruction and the indications for amputation. Where there are no clear data, a balanced view of the available evidence is presented, with recommendations based on principles and experience. Importantly, they have also detailed how outcomes can be assessed. I am delighted to note that the intention is for the specialist centres to audit their outcomes using the evidence-based standards. Often neglected are

ways to deal with problems when things go wrong, and again the authors have addressed this important area.

The recommendation for the patients to be transferred directly to specialist centres reflects my proposals in the NHS Next Stage Review for the treatment of major trauma in specialist centres.

This publication is aimed at improving the quality of treatment through education. BAPRAS and BOA are to be commended for making the entire publication available online via their websites and free to download in PDF format, as well as producing this abridged version of the principal guidelines. The BOAST poster should enable the Standards to be widely publicised.

Our NHS has been at the forefront of numerous innovations and it is heartening to see that the authors have drawn on a wealth of international knowledge to set the highest standards for patient care.

**Professor, the Lord Darzi of Denham KBE,
HonFREng, FmedSci**



Plastic surgery is by its nature one of the most collaborative specialties, forming part of many different care teams. No cooperation has been so strong or productive as that alliance with orthopaedic and trauma surgery, and this was underlined in the revolution in the care of the mangled limb, and especially the open tibial fracture.

When in 1986 Marco Godina demonstrated how to manage these injuries with the full benefit of the emerging field of microvascular transplantation, he presaged a new era in salvaging limbs. This would not have been possible without the advances in fracture fixation, nor the skills and knowledge in soft tissue debridement and repair. But it has been the synergy between these disciplines and the remarkable cooperation between teams all over the world that has wrought this change most emphatically.

The first UK guidance on the joint management of lower limb trauma came from the BOA and the (then) BAPS in 1993 and this present guidance follows in the same tradition. However now, in a contemporary manner, the guidance is more specific, more comprehensive, and evidence-based. These standards

will prove invaluable to teams around the world and the joint working party is owed a debt of gratitude from all managing trauma and from all those patients who will surely benefit in years to come.

**Professor Simon Kay
President, BAPRAS**



I am delighted to see the publication of *Standards for the management of open fractures of the lower limb*. This is an excellent example of how the two Specialist Associations, BAPRAS and BOA, can work together to set standards and give practical guidance to surgeons dealing with these complex injuries.

I would encourage all orthopaedic surgeons involved in trauma care to ensure that the BOAST and the joint booklet are seen by as wide an audience as possible to ensure that standards of care are improved and assured for the future. The BOA also recommends those wishing to have more detailed information to purchase the excellent book to be published by the Joint Working Party.

Clare Marx
President, BOA

The first meeting between the British Orthopaedic Association (BOA) and the British Association of Plastic, Reconstructive and Aesthetic Surgeons (BAPRAS) was convened in 1991 to foster closer working between the specialties for the management of patients with open tibial fractures.

There was a clear consensus that they should be managed jointly and in 1993 and again in 1997, representatives from both associations published guidelines for the management of open tibial fractures. The main aims were to promote cooperation between orthopaedic and plastic surgeons, improve the understanding of these uncommon but complex injuries and encourage their treatment in specialist centres. However, the publication went beyond these, providing an algorithmic approach to the management of the injuries and guidance on 'how to do it'. At a subsequent meeting of the two associations in 2003, it was clear there were difficulties in following the guidelines owing to geographical constraints, lack of resources and remaining areas of clinical controversy.

In 2007, the BOA and the BAPRAS nominated representatives to update the guidelines. An increasing awareness of the complexity of these injuries and an appreciation of limitations of previous classifications to predict outcome prompted the working group to examine the published literature in all areas pertaining to the management of open fractures of the lower limb with a particular focus on injuries below the knee. As in other areas of surgery, there were few randomised trials and an approach based purely on levels of evidence would not have been possible. However, we have been able to draw on a wealth of excellent publications and endeavoured to put the available evidence in context. Where there is no clear consensus, we have drawn on data from associated areas and on our experience. If no clear choice between available alternatives for management was present, we have tried to provide a balanced view through highlighting the relative merits and drawbacks of each. The evidence-base upon which we have drawn is publications in English. We are delighted that the British Infection Society and the Association of Medical Microbiologists have reviewed the guidelines for antibiotic prophylaxis. The format is designed to give the reader easy access to the principal recommendations. Details on how they were derived and a bibliography of the relevant literature can be found in the full *Standards* publication.

Finally, this publication reflects the current evidence-base for our recommendations and we are unanimous in the view that these are the standards of care every patient with these injuries should receive. These recommendations should find application beyond the UK.

BAPRAS and BOA established a working group with experienced clinicians to define the standards for the management of open fractures of the lower limb. The authors are all practicing specialists in the UK with a particular interest in the evidence-based management of open fractures of the lower limb, from an orthopaedic, plastic surgery and infection control viewpoint.

Authors:

Jagdeep Nanchahal

Professor of Hand, Plastic & Reconstructive Surgery, London

Selvadurai Nayagam

Consultant Orthopaedic Surgeon, Liverpool

Umraz Khan

Consultant Plastic Surgeon, Bristol

Christopher Moran

Professor of Trauma & Orthopaedic Surgery, Nottingham

Stephen Barrett

Consultant in Medical Microbiology, Southend

Frances Sanderson

Consultant in Infectious Diseases, London

Ian Pallister

Reader in Trauma & Orthopaedic surgery, Swansea

Managing editor:

Hamish Laing

Consultant Plastic Surgeon, Swansea

The recommendations that follow are a summary of the main standards publication – *Standards for the management of open fractures of the lower limb*. Each section heading below corresponds to a chapter within the full standards publication.

1. Specialist centres

Principal recommendations

- A multidisciplinary team, including orthopaedic and plastic surgeons with appropriate experience, is required for the treatment of complex open fractures.
- Hospitals which lack a team with requisite expertise to treat complex open fractures have arrangements for immediate referral to the nearest specialist centre.
- The primary surgical treatment (wound debridement/excision and skeletal stabilisation) of these complex injuries takes place at the specialist centre whenever possible.
- Specialist centres for the management of severe open fractures are organised on a regional basis as part of a regional trauma system. Usually these centres also provide the regional service for major trauma.

The characteristics of *open* injuries that should prompt referral to a specialist centre are based on:

1. Fracture patterns:

- (a) Transverse or short oblique tibial fractures with fibular fractures at a similar level
- (b) Tibial fractures with comminution/butterfly fragments with fibular fractures at a similar level
- (c) Segmental tibial fractures
- (d) Fractures with bone loss, either from extrusion at the time of injury or after debridement.

2. Soft tissue injury patterns:

- (a) Skin loss such that direct tension-free closure is not possible following wound excision
- (b) Degloving
- (c) Injury to the muscles which requires excision of devitalised muscle via wound extensions
- (d) Injury to one or more of the major arteries of the leg.

The specialist centre will need to:

- Include orthopaedic trauma surgery, with special expertise in complex tibial fractures and bone reconstruction.
- Include plastic and microvascular surgery, with expertise in vascular reconstruction.

PRINCIPAL RECOMMENDATIONS

- Provide facilities for simultaneous debridement by orthopaedic and plastic surgical teams.
- Ensure orthopaedic and plastic surgical planning of management strategy to avoid multiple episodes of treatment, thereby ensuring efficient and optimal patient care.
- Provide dedicated theatre sessions for the combined orthoplastic management of the patients during the normal working day.
- Include microbiology and infectious disease consultants with expertise in musculoskeletal infection.
- Include facilities for emergency musculoskeletal imaging, with angiography and interventional radiology.
- Provide a service for, or have access to, artificial limb fitting and rehabilitation for amputees.
- Have access to physical and psychosocial rehabilitation services.
- Include audit of outcome as part of the care pathway.
- Aim to reach a throughput of 30 such cases per annum to maintain appropriate skill and experience levels.
- Provide combined orthoplastic clinics and multidisciplinary ward rounds.
- Possess intensive care and other trauma facilities for the multiply injured patient.

2. Primary management in the emergency department

Principal recommendations

- Initial assessment and treatment of the patient occurs simultaneously and in accordance with Advanced Trauma Life Support (ATLS®) principles.
- Assessment of the open tibial injury is systematic, careful and repeated in order to identify established or evolving limb-threatening conditions and to document limb status prior to manipulation or surgery.
- Haemorrhage control is through direct pressure or, as a last resort, application of a tourniquet.
- Wounds are handled only to
 - a. Remove gross contaminants
 - b. Photograph for record
 - c. Seal from the environment.
- Wounds are not 'provisionally cleaned' either by:
 - a. exploration
 - b. irrigation.

- Limb splintage is the most appropriate means of immobilisation available in the Emergency Department. Provisional external fixators are not applied.
- Antibiotic and anti-tetanus prophylaxis is given.
- In addition to two orthogonal views of the tibia, radiographic assessment includes the knee and ankle joints.

3. Antibiotic prophylaxis

Principal recommendations

- Antibiotics should be administered as soon as possible after the injury, and certainly within three hours.
- The antibiotic of choice is co-amoxiclav (1.2g 8 hourly), or a cephalosporin (eg cefuroxime 1.5g 8 hourly), and this should be continued until first debridement (excision).
- At the time of first debridement, co-amoxiclav (1.2g) or a cephalosporin (such as cefuroxime 1.5 g) and gentamicin (1.5 mg/kg) should be administered and co-amoxiclav/cephalosporin continued until soft tissue closure or for a maximum of 72 hours, whichever is sooner.
- Gentamicin 1.5 mg/kg and either vancomycin 1g or teicoplanin 800mg should be administered on induction of anaesthesia at the time of skeletal stabilisation and definitive soft tissue closure. These should not be continued post-operatively. The vancomycin infusion should be started at least 90 minutes prior to surgery.
- Patients with anaphylaxis to penicillin should receive clindamycin (600mg iv pre-op/qds) in place of co-amoxiclav/cephalosporin. For those with lesser allergic reactions a cephalosporin is considered to be safe and is the agent of choice.

4. Timing of wound excision in open fractures

Principal recommendations

- Broad spectrum antibiotics are administered as soon after the injury as possible.
- The only reasons for immediate surgical exploration are the presence of:
 - a. Gross contamination of the wound
 - b. Compartment syndrome
 - c. A devascularised limb
 - d. A multiply injured patient.

PRINCIPAL RECOMMENDATIONS

- In the absence of these criteria, the wound, soft tissue and bone excision (debridement) is performed by senior plastic and orthopaedic surgeons working together on scheduled trauma operating lists within normal working hours and within 24 hours of the injury unless there is marine, agricultural or sewage contamination. The 6 hour rule does not apply for solitary open fractures.

5. Guidelines for wound debridement (excision)

Principal recommendations

- Early, accurate debridement of the traumatic wound is the most important surgical procedure in the management of open tibial fractures.
- Debridement means excision of all devitalised tissue (except neurovascular bundles).
- Traumatic wounds are excised comprehensively and systematically and the following sequence is followed in all cases:
 - Initially, the limb is washed with a soapy solution and a tourniquet is applied
 - The limb is then 'prepped' with an alcoholic chlorhexidine solution, avoiding contact of the antiseptic with the open wound and pooling under the tourniquet
 - Soft tissue debridement/excision is safely performed under tourniquet control, especially in cases of extensive degloving. This allows identification of key structures such as neurovascular bundles, which may be displaced, and permits accurate examination of tissues by avoiding blood-staining
 - Visualisation of the deeper structures is facilitated by wound extensions along the fasciotomy lines, described in section 13, page 17
 - The tissues are assessed systematically in turn, from superficial to deep (skin, fat, muscle, bone) and from the periphery to the centre of the wound. Non-viable skin, fat, muscle and bone is excised
 - At this stage the injury can be classified and definitive reconstruction planned jointly by the senior members of the orthopaedic and plastic surgical team
 - If definitive skeletal and soft tissue reconstruction is not to be undertaken in a single stage, then a vacuum foam dressing (or antibiotic bead pouch if significant segmental bone has been lost) is applied until definitive surgery is performed.

6. Bone exposure, decontamination and preservation: debridement

Principal recommendations

- Extension of the traumatic wound is along the nearest fasciotomy incision (see section 13, page 17).
- Whilst a bloodless field during soft tissue debridement may be helpful, deflating the tourniquet before bone debridement allows satisfactory confirmation of a 'capacity of the bone ends to bleed'. This is probably the most useful determinant of bone viability.
- Careful surgical delivery of bone ends through the wound extension aids circumferential assessment.
- Particulate foreign matter is removed with periodic irrigation to keep clear visibility of the surgical field.
- Loose fragments of bone which fail the 'tug test' are removed.
- Fracture ends and larger fragments which fail to demonstrate signs of viability are removed.
- Major articular fragments are preserved as long as they can be reduced and fixed with absolute stability.
- Lavage follows, once a clean wound is obtained by a meticulous zone-by-zone debridement.
- High pressure pulsatile lavage is not recommended.

7. Degloving

Principal recommendations

- Degloving of the limb occurs in the plane superficial to the deep fascia and the extent of injury is often underestimated.
- Thrombosis of the subcutaneous veins usually indicates the need to excise the overlying skin.
- Circumferential degloving often indicates that the involved skin is not viable.
- In severe injuries, multi-planar degloving can occur with variable involvement of individual muscles, and these may be stripped from the bone. Under these circumstances, a second look may be necessary to ensure that all the non-viable tissues have been excised prior to definitive reconstruction within seven days.

8. Classification of open fractures

Principal recommendations

- Accurate, simple and reproducible systems for classification of lower limb injuries facilitate communication between health care professionals, assist transfer of appropriate cases to specialist centres and should lead to a treatment plan.

PRINCIPAL RECOMMENDATIONS

- They provide a platform for conducting detailed audit of care to ensure optimal management of these patients.
- The Gustilo and Anderson grading is widely used and is relatively simple, but has poor inter-observer reliability and is best applied after wound excision.
- Others, such as the AO system, are comprehensive systems best used for audit and data collection of outcomes.

9. Temporary wound dressings

Principal recommendations

- Negative pressure dressings may reduce bacterial ingress and tissue desiccation as well as avoid pooling of serous fluid.
- Negative pressure dressings are not used as a substitute for meticulous surgical wound excision.
- Negative pressure dressings are not a substitute for coverage of exposed fractures with vascularised flaps.
- Antibiotic impregnated bone cement beads under a semi-permeable membrane are associated with reduced infection rates.
- These beads are most applicable in patients with segmental bone loss, gross contamination or established infection, perhaps in combination with negative pressure dressings.

10. Techniques for skeletal stabilisation in open tibial fractures

Principal recommendations

- Spanning external fixation is recommended when definitive fracture stabilisation and immediate wound cover is not carried out at the time of primary debridement.
- Fracture patterns and bone loss determine the most appropriate form of definitive skeletal stabilisation.
- Exchange from spanning external fixation to internal fixation is done as early as possible.
- Internal fixation is safe if there is minimal contamination and soft tissue coverage is achieved at the same time as insertion of the implant.
- Modern multiplanar and circular fixators are used if there is significant contamination, bone loss and multilevel fractures of the tibia.

Safe corridors for pin placement in the tibia

The tibia can be conveniently divided into three segments in which the safe corridors are relatively constant.

Figure 1

In **segment one**, the posterior tibial neurovascular bundle lies close to the midline and directly behind the posterior cortex. Obliquely-directed screws avoid accidental injury.

In **segment two**, a 'buffer' of the deep posterior compartment muscles lies between the posterior cortex of the tibia and the posterior tibial neurovascular bundle. Although anteromedial placement is popular, anterior to posterior screws are safe as long as care is taken to avoid over-penetration. These sagittal plane screws are useful as they give good access for plastic surgical procedures on either side of the sagittal plane of the limb.

In **segment three**, the anterior to posterior screw is inserted through a small incision and the plane between the lateral edge of tibialis anterior and extensor hallucis longus found. An anteromedial screw is also useful but attention needs to be paid to avoid tethering the medial skin in the event a distally-based fasciocutaneous flap is needed for fracture cover.

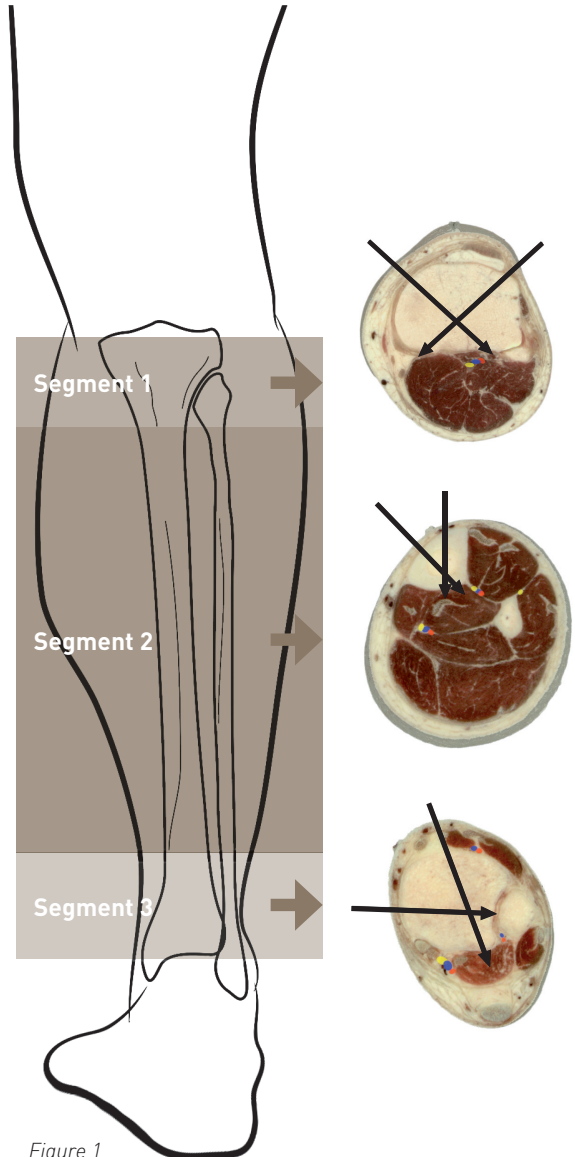


Figure 1

PRINCIPAL RECOMMENDATIONS

Figure 2a

Pins inserted about 1cm medial to the tibial crest and directed posteriorly allow a simple sagittal plane spanning fixator to be constructed. This provides good access for most plastic surgical procedures.

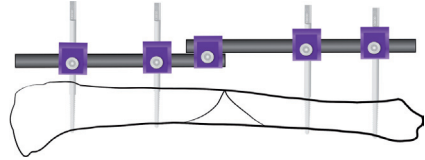


Figure 2a

Figure 2b

The tibial pins are inserted in the sagittal plane approximately 1cm medial to the crest. Two coronal plane pins are inserted in the os calcis and neck of talus on the medial side. This arrangement provides good control of the distal tibia by eliminating hindfoot movement. Alternative pin placement includes the base of the first and fifth metatarsals but smaller diameter pins should be used in these areas.

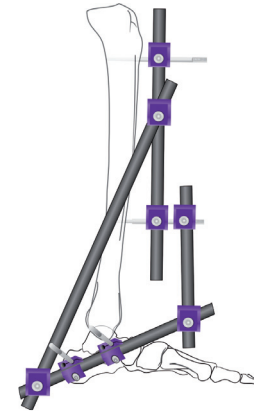


Figure 2b

Figure 2c

Access to the medial aspect of the distal tibia for plastic surgical procedures is facilitated by altering the position of the oblique posterior connecting rod as shown. The rod is returned to its original position after the procedure or the spanning fixator replaced by definitive stabilisation.

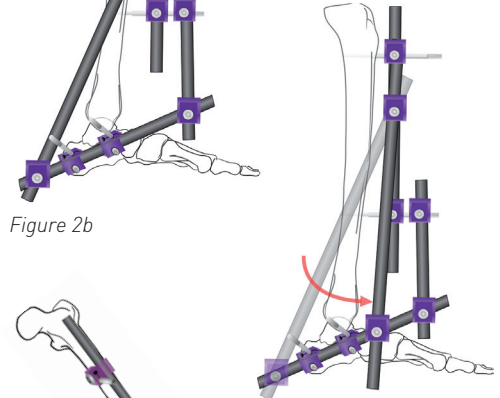


Figure 2c

Figure 2d

Control of knee movement (which occurs in the sagittal plane) and access to the front and rear of the proximal tibia are two requisites of the spanning fixator in open proximal tibial fractures. The first is achieved by using sagittal plane pins in both tibia and femur; an additional anterolateral pin in the distal femur significantly improves the stability of the construct. The second is met by keeping the tibial pins distal to the junction of proximal and middle tibia, thereby permitting easy access for potential soft tissue reconstruction using either local or free vascularised tissue.

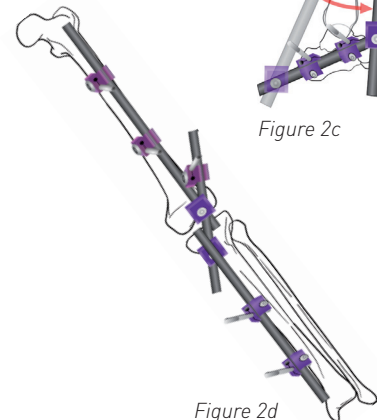


Figure 2d

11. Timing of soft tissue reconstruction

Principal recommendations

- Local flaps are safely performed at the same time as skeletal fixation. Internal fixation is only undertaken if soft tissue coverage can be performed at the same time.
- Free flap reconstruction is best performed on scheduled trauma lists by experienced, dedicated senior surgical teams following adequate preparation of the patient, including imaging such as angiography or CT scanning of comminuted fractures. This should be undertaken in a specialist centre.
- There is little evidence for the five-day rule. Microsurgery is best performed before the vessels become friable or fibrosed and this becomes increasingly likely after the first week. We recommend that definitive soft tissue reconstruction be undertaken within the first seven days after injury.

12. Type of soft tissue reconstruction

Principal recommendations

- All open fractures are covered with vascularised soft tissue.
- Dressings such as those using foam with negative pressure can temporise following wound excision, but are not to be used as a substitute for definitive flap coverage.
- Relatively low energy tibial fractures are covered by local fasciocutaneous flaps so long as the vascularity has not been compromised by the zone of injury and degloving.
- Strong clinical evidence to support the use of one form of soft tissue cover over another in open tibial shaft fractures is absent. However, available experimental data would suggest that diaphyseal tibial fractures with periosteal stripping are best covered by muscle flaps instead of fasciocutaneous flaps.
- Metaphyseal fractures, especially those around the ankle, are best covered by fasciocutaneous flaps, including free flaps.

13. Compartment syndrome

Principal recommendations

- Compartment syndrome is a surgical emergency and must be diagnosed promptly and treated.
- The early signs are paraesthesia in the distribution of the sensory nerves passing through the affected compartment and disproportionate pain, especially on passive stretch of the affected muscles.
- These important signs may be affected by the previous administration of peripheral nerve blocks and regional anaesthesia, as well as by the presence of nerve injury.

PRINCIPAL RECOMMENDATIONS

- Compartment syndrome does not usually result in the loss of peripheral pulses. Absent pulses should alert the surgeon to the possibility of vascular injury.
- Intra-compartment pressure measurement is performed most reliably using devices designed specifically for this purpose. A difference of 30mmHg or less between the measured pressure and the diastolic blood pressure is a reasonable threshold for decompression.
- Every effort is made to achieve an accurate diagnosis because inappropriate fasciotomy can be associated with significant morbidity.
- The two incision technique provides optimal access for four compartment decompression. The medial incision does not compromise the availability of available local fasciocutaneous flaps. It can also be used to extend pre-existing traumatic lacerations to achieve access for debridement as well as provide an approach to the posterior tibial vessels as recipient vessels for free flaps.
- All non-viable muscle is excised and fasciotomy wounds either closed with split skin grafts or directly, if possible, once the swelling has reduced.
- A late diagnosis of compartment syndrome is a management dilemma. Once the muscle is no longer viable, compartment release will predispose to infection, and may result in compartmentectomy or amputation of the limb.

Figure 3 – Recommended approach to the four compartments of the leg

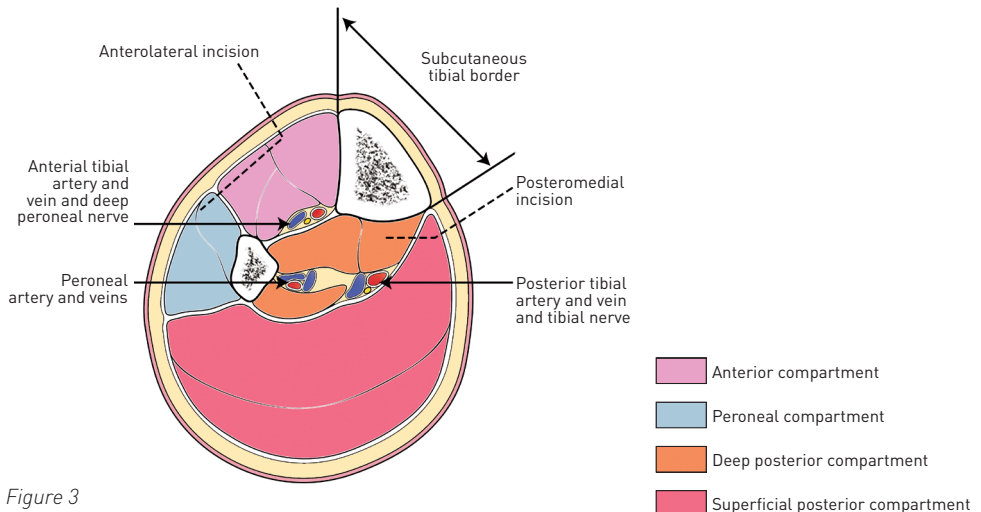


Figure 3

Figure 4 – Landmarks, major vessels and their perforators to be preserved

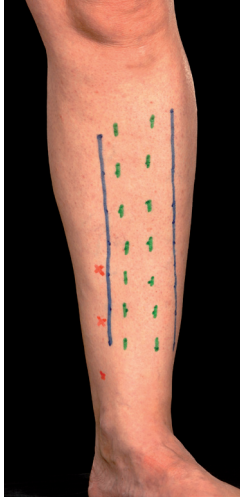


Figure 4a

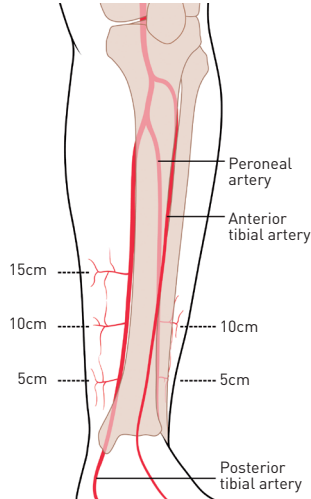


Figure 4b

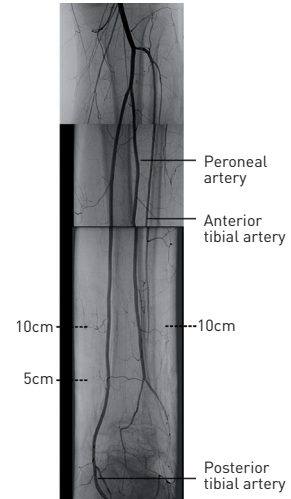


Figure 4c

Recommended incisions for fasciotomy and wound extensions. (a) Margins of subcutaneous border of tibia marked in green, fasciotomy incisions in blue and the perforators on the medial side arising from the posterior tibial vessels in red. (b) line drawing depicting the location of the perforators. (c) montage of an arteriogram. The 10cm perforator on the medial side is usually the largest and most reliable for distally-based fasciocutaneous flaps. In this patient, the anterior tibial artery had been disrupted following an open dislocation of the ankle; hence the poor flow evident in this vessel in the distal 1/3 of the leg. The distances of the perforators from the tip of the medial malleolus are approximate and vary between patients. It is essential to preserve the perforators and avoid incisions crossing the line between them.

14. Vascular injuries

Principal recommendations

- Devascularised limbs are a surgical emergency. They are recognised immediately and require urgent surgical exploration. The aim is to restore circulation within three to four hours of the injury, after which muscle death begins. The maximum acceptable delay is six hours of warm ischaemia time.
- Capillary refill in the toes can be misleading and, if the circulation is not normal compared to the contralateral limb, there is a low threshold for exploration.

PRINCIPAL RECOMMENDATIONS

- Absent peripheral pulses are not attributed to vascular spasm or compartment syndrome. A major vascular injury is always considered and senior surgical opinion is sought.
- Preoperative angiography in the devascularised limb wastes valuable time. It is possible to define the level of injury from the fracture configuration and any site of dislocation.
- Shunting significantly reduces the morbidity associated with these injuries by reducing the ischaemic time. Muscle suffers irreversible ischaemic damage within three to four hours of complete ischaemia. Nerves are also susceptible to ischaemic injury.
- Once the circulation is restored, the limb is reassessed with regard to the potential for salvage.
- The skeleton is then stabilised before replacing the shunts with reversed vein grafts.
- Proximal to the level of the trifurcation, any deep venous injury is also reconstructed.
- Access incisions for vascular repair take into account the necessity for flap cover and the presence of adjacent fractures.
- Fasciotomy is performed if indicated by the presence of raised intra-compartmental pressures compared to the diastolic blood pressure. However, it is important that these measurements are performed repeatedly, as muscle swelling may not develop until several hours after revascularisation [see section 13].
- The presence of a single patent artery to the foot is not a contraindication to free flap reconstruction using end-to-side anastomoses. In this situation, reconstruction of the injured vessels is considered, especially the posterior tibial artery.

15. Open fractures of the foot and ankle

Principal recommendations

- These are particularly challenging injuries owing to the limited local soft tissue flap options, likelihood of injury to the neurovascular bundles, intra-articular fractures predisposing to poor long term function, and difficulty in stabilising the fractures.
- Amputation is considered when the final functional outcome following reconstruction is likely to be inferior to a trans-tibial amputation. This is especially likely to be the case for a 'floating ankle' injury or crush injuries with an open mid- and forefoot.
- Initial skeletal stabilisation is achieved with a spanning external fixator, avoiding fibular plating. There are inherent difficulties in stabilising these fractures as the anchor points for most spanning external fixators rely on an intact os calcis/talus/metatarsals.
- Definitive skeletal fixation is performed at the time of soft tissue coverage. The exact configuration will depend on the fracture pattern, with intra-articular fractures usually best managed by internal fixation. Internal fixation is not recommended in the absence of adequate soft tissue cover, as this may be associated with an increased risk of deep sepsis.
- Degloved plantar skin:
 - a. If suprafascial, is defatted and replaced as full-thickness graft

- b. If subfascial and proximally based, is sutured back without tension
- c. If subfascial and distally based, is considered for revascularisation.
- Plantar soft tissue loss is best managed using fasciocutaneous flaps, and reinnervation may confer some protection against the development of neuropathic ulceration. Dorsal skin loss can be managed by split skin grafts or thin, free fasciocutaneous flaps.
- Open pilon fractures are stabilised with a spanning external fixator. If the planned definitive treatment is internal fixation of the tibial plafond, and provided the soft tissues permit, open reduction and internal fixation of the fibula at primary surgery may help to assist maintain the limb out to length. Soft-tissue cover should be by way of thin, pliable fasciocutaneous flaps.
- Injuries to the posterior tibial nerve are accurately assessed and consideration is given to reconstruction of segmental defects of the posterior tibial artery with autologous vascular graft. End-to-end anastomoses to avulsed vessels are performed with care as it can be difficult to assess the extent of intimal damage.
- Open hind-foot injuries are managed as for a diaphyseal injury when only one articular surface is involved. When there is greater disruption of the hind-foot, a trans-tibial amputation is considered.
- Isolated open mid-foot injuries are often caused by heavy objects falling on the foot. These result in significant post-operative stiffness and pain due to ligamentous disruption and again, amputation is considered.
- Open forefoot injuries involving the first metatarsal are treated as aggressively as open diaphyseal injuries. When the other metatarsals are injured in isolation, a ray amputation results in a reasonable return to ambulation.

16. When things go wrong with soft tissues

Principal recommendations

- Necrosis of a local flap over the fracture site is managed by early return to theatre and revision surgery to achieve healthy soft tissue coverage.
- Limited tip congestion may respond to leech therapy.
- Some local fasciocutaneous flaps may be more prone to develop complications in patients with co-morbidities.
- Free flap complications are reduced by patient preparation, careful planning and performing the anastomoses outside the zone of injury, ideally proximally.
- There is a low threshold for immediate re-exploration of a free flap with suspected circulatory compromise.
- Deep infection requires a return to fracture site exploration, debridement, dead space management and antibiotic therapy. Fracture fixation may need revision.

17. When things go wrong with bone

Principal recommendations

- Early complications with bone occur as a consequence of the original injury or from surgery.
- Problems that present are:
 - a. wound leakage
 - b. sepsis
 - c. loss of alignment.
- Common causes include inadequate debridement, haematoma formation, inappropriate or delayed soft tissue cover and unstable fixation. Each cause is sought and remedied promptly.
- An expectant approach is seldom fruitful and, if adopted, should be for a limited period only.
- A decision to intervene is taken if there is failure to improve.
- Early problems can exert an undue influence on the final outcome unless weighed for their significance and acted upon appropriately and promptly.
- Discussion of the case with the nearest specialist centre is encouraged and gives the opportunity to correct the problem at the earliest opportunity.

18. Guidelines for primary amputation

Principal recommendations

- A primary amputation is performed as a damage control procedure if there is uncontrollable haemorrhage from the open tibial injury (usually from multiple levels of arterial / venous damage in blast injuries), or for crush injuries exceeding a warm ischaemic period of six hours.
- Primary amputation is also needed for incomplete traumatic amputations where the distal remnant is significantly injured.
- A primary amputation is considered an option when injury characteristics include one or several of the following:
 - avascular limbs exceeding a four to six hour threshold of warm ischaemia
 - segmental muscle loss affecting more than two compartments
 - segmental bone loss greater than one third the length of the tibia.
- Absent or reduced plantar sensation at initial presentation is not an indication for amputation.
- Amputation levels are preferably trans-tibial or trans-femoral (if salvage of the knee is not possible). Through-the-knee amputations are not recommended for adults.

- The decision to amputate primarily should be taken by two consultant surgeons with, if possible, patient and family involvement.
- Discussion with the nearest specialist centre is advised when there is uncertainty or disagreement between surgeon recommendations and patient/family wishes.

19. Outcome measures

Principal recommendations

- Patient health status questionnaires such as Sickness Impact Profile and Medical Outcomes Study Short Form-36 (SF-36) provide a valuable overall assessment of the patient.
- Union time of diaphyseal fractures can be difficult to assess but is an accepted outcome measure.
- Rates of significant complications such as deep infection, flap failure and secondary amputation are recorded.
- Limb function scores such as the Enneking Score, which is expressed as a percentage of the contralateral uninjured limb, are recommended.
- Peri-articular injuries ideally should include measures of the affected joints.

20. Management of severe open fractures in children

Principal recommendations

- The wound for open children's fractures is debrided (excised) as recommended for adults. There is no evidence to suggest that tissues with compromised viability are more likely to recover in children compared to adults.
- Skeletal fixation is determined by the fracture configuration. The use of intramedullary devices may be limited by the presence of growth plates.
- The available evidence suggests that children under the age of twelve years (prepubertal) are likely to have shorter union times.
- Soft tissue reconstruction for open fractures in children of all ages relies on vascularised flaps, as it does for adults.



BAPRAS

British Association of Plastic
Reconstructive and Aesthetic Surgeons

British
Orthopaedic
Association



BAPRAS

BAPRAS, the British Association of Plastic, Reconstructive and Aesthetic Surgeons, is the voice of plastic surgery in the UK. It aims to increase the understanding of the professional specialty and scope of plastic surgery, promoting innovation in teaching, learning and research. Founded in 1946 (originally as the British Association of Plastic Surgeons), today BAPRAS has over 800 members and is the professional representative body for reconstructive and aesthetic plastic surgeons providing services to patients on the NHS and privately in the UK.

The British Association of Plastic, Reconstructive and Aesthetic Surgeons (BAPRAS)

35-43 Lincoln's Inn Fields, London WC2A 3PE,

Telephone: 020 7831 5161, Fax: 020 7831 4041

www.bapras.org.uk

BOA

The BOA is the professional association for trauma and orthopaedic surgeons in the UK and those abroad who have had orthopaedic training in the UK or who show a continuing interest in the affairs of the Association. Founded in 1918, our mission is to bring relief to people suffering from injury or musculoskeletal disorder by advancing the science, art and practice of orthopaedic surgery. The BOA currently has about 4000 members in the UK and overseas, the majority of these are UK consultant and trainee orthopaedic surgeons.

The British Orthopaedic Association (BOA)

35-43 Lincoln's Inn Fields, London WC2A 3PE,

Telephone: 020 7405 6507, Fax: 020 7831 2676

www.boa.ac.uk

ACKNOWLEDGEMENTS

We are grateful that the publication of these standards has been supported with educational grants from: De Puy, Orthofix, Smith & Nephew and Synthes.

 **DePuy**
a депуй-депуй company *never stop moving[®]*


ORTHOFIX

 **smith&nephew**

 **SYNTHES**[®] Instruments and implants
approved by the AO Foundation